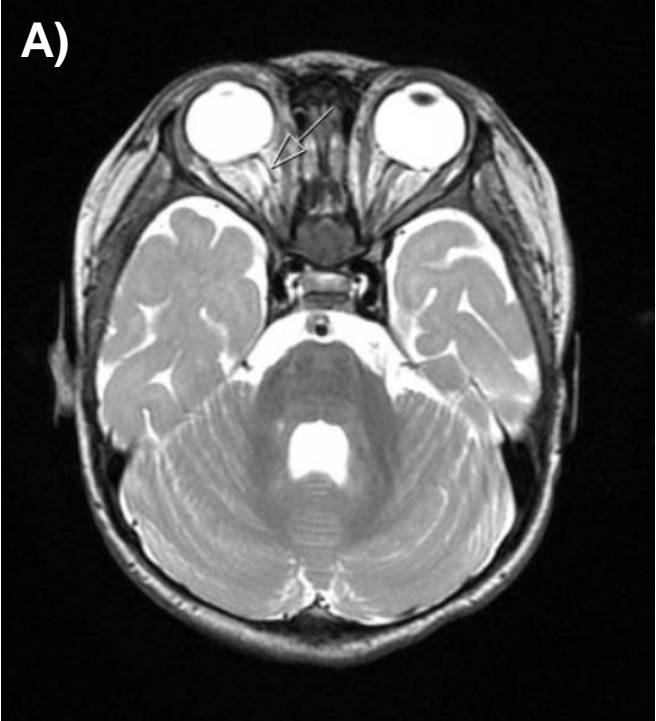

B)

Day +158

Day +226

Day +517

Day +694

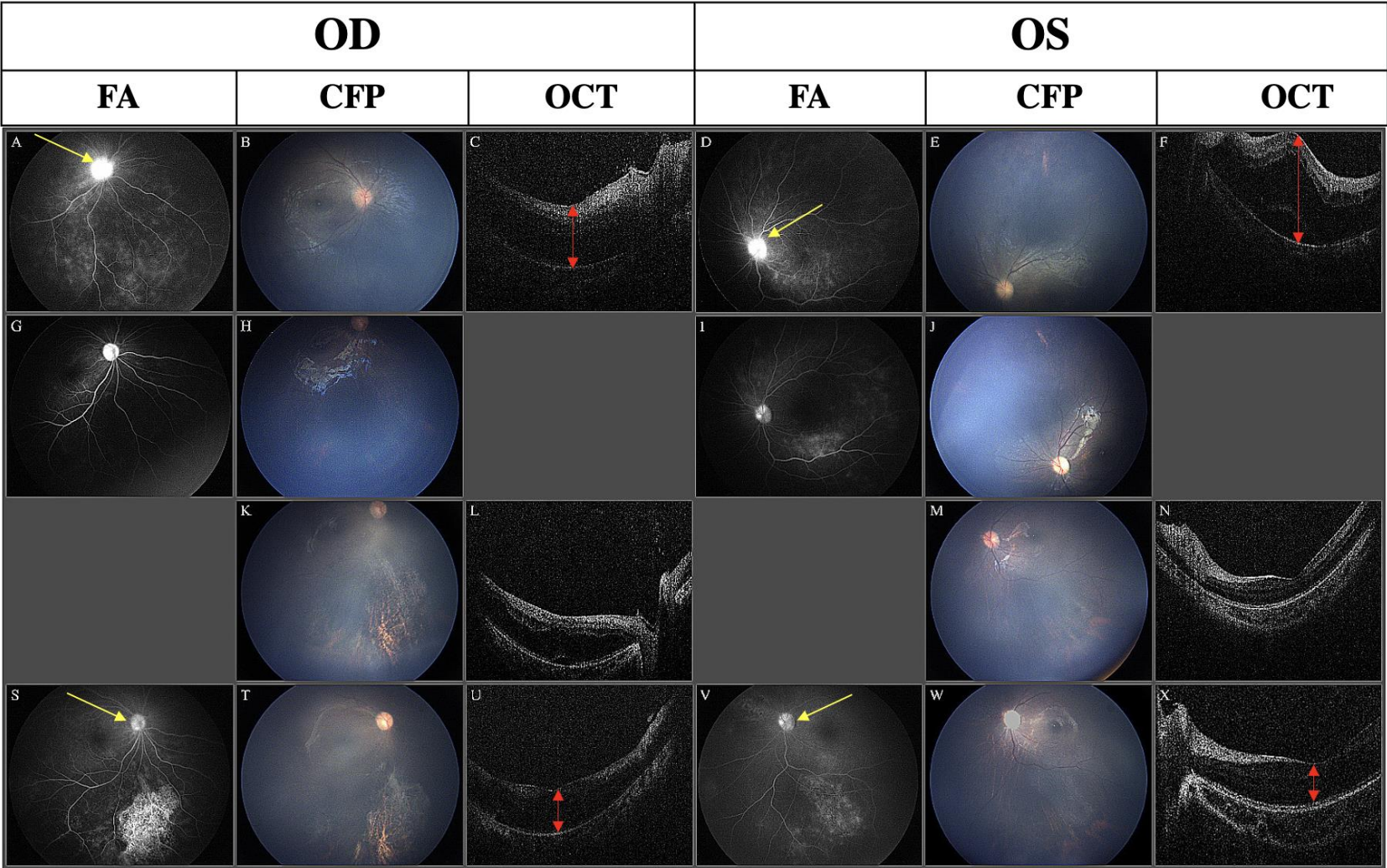


Figure 2. A) MRI Brain on day of CMVR recurrence (Day +158 post-HCT) showing right optic nerve enhancement. **B)** Composite of Fluorescein Angiography (FA), Color Fundus Photography (CFP), and Optical Coherence Tomography B-scans (OCT) of right (OD) and left eye (OS), respectively. Grey panels indicate no imaging from the patient was collected on that date. Panels A-F: imaging from initial exam under anesthesia (Day +158 post-HCT). Panels G-J: imaging from time of quiescence prior to initiation of tocilizumab (Day +226 post-HCT). Panels K-N: imaging from 6 months after final tocilizumab infusion and 2 rounds of VST therapy (Day +517 post-HCT). Panels S-X: imaging from most recent EUA with quiescence and improvement after 3 rounds of VST therapy (Day +694 post-HCT). Yellow arrows show progressive decrease in optic disc edema and retinal vasculitis (represented by decreased hyperfluorescence in angiogram) and red arrows show progressive decrease in macular edema (represented by decreased retinal thickening on OCT) in both eyes.