

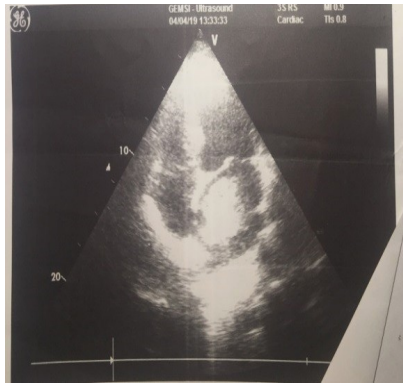Figure (1):- TTE was showing mass in atrium

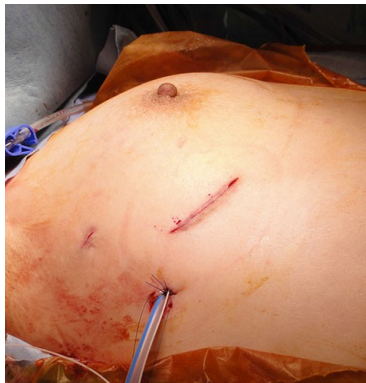

Figure (2):- Mini-thoracotomy approach

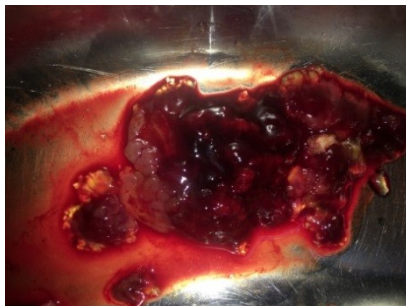


Figure (3):- Soft friable myxoma specimen

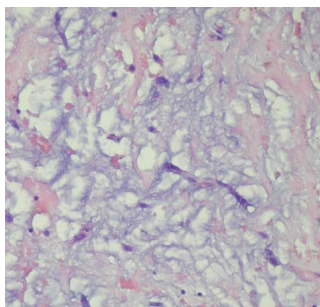


Figure (4):- Pathological photo of myxoma