

Figure

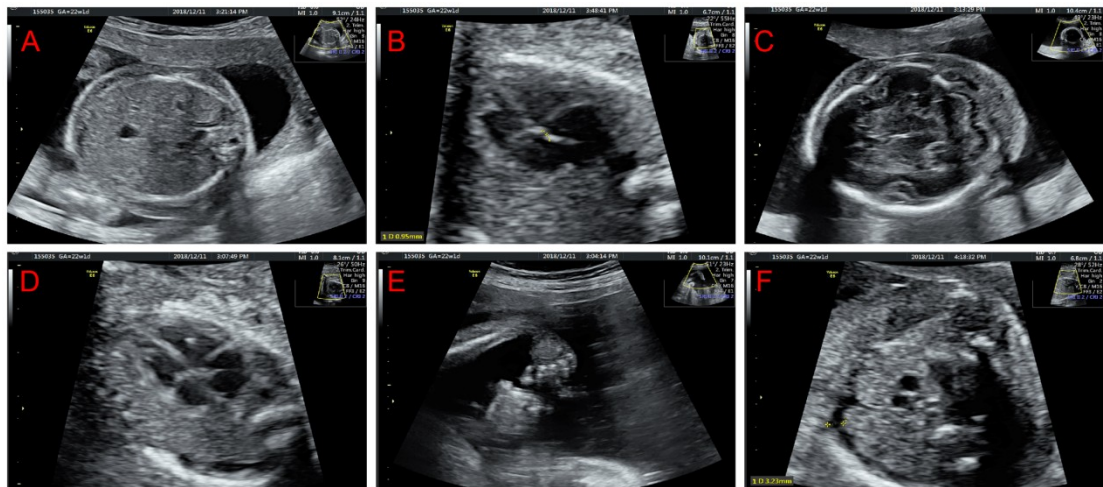


Figure1. Partial ultrasound abnormalities of the fetus

A. small stomach , B. atrial septal defects , C. subcutaneous edema , D. left pulmonary hypoplasia, E. limbs contracture , F. right pleural effusion

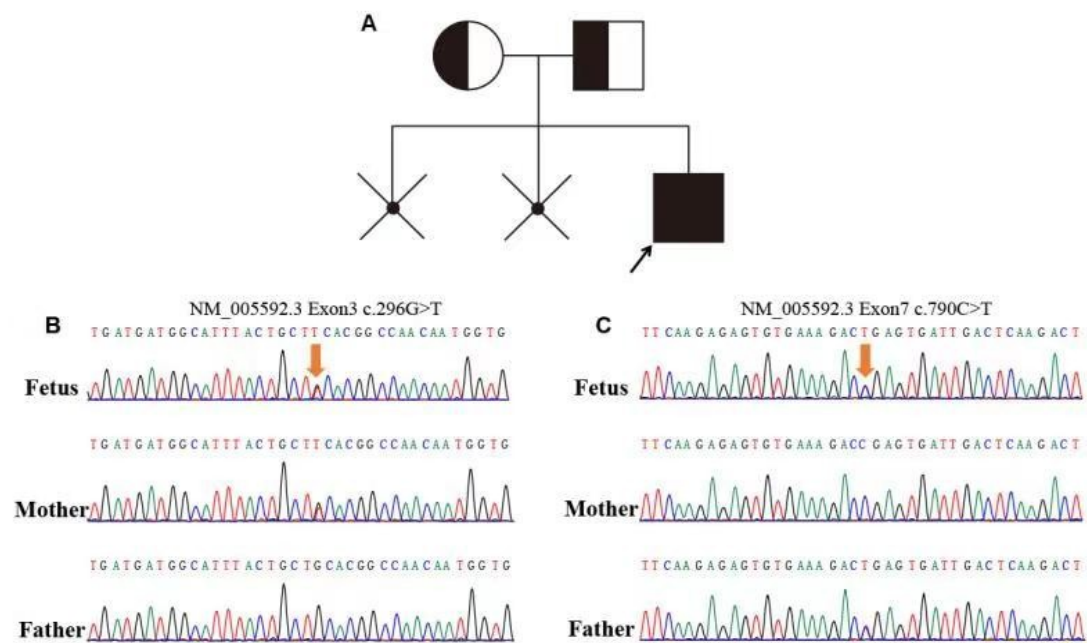


Figure 2. Sanger sequencing traces for the parents and proband for the *MuSK* gene positions. Pedigree of affected family displays two adverse pregnancy outcomes and one affected fetus.

Figure A Pedigree of affected family displays two negative pregnancy outcomes and one affected fetus

Figure B/C Sanger sequencing revealed that the mother and father were heterozygous for the mutation, the affected fetus was homozygous