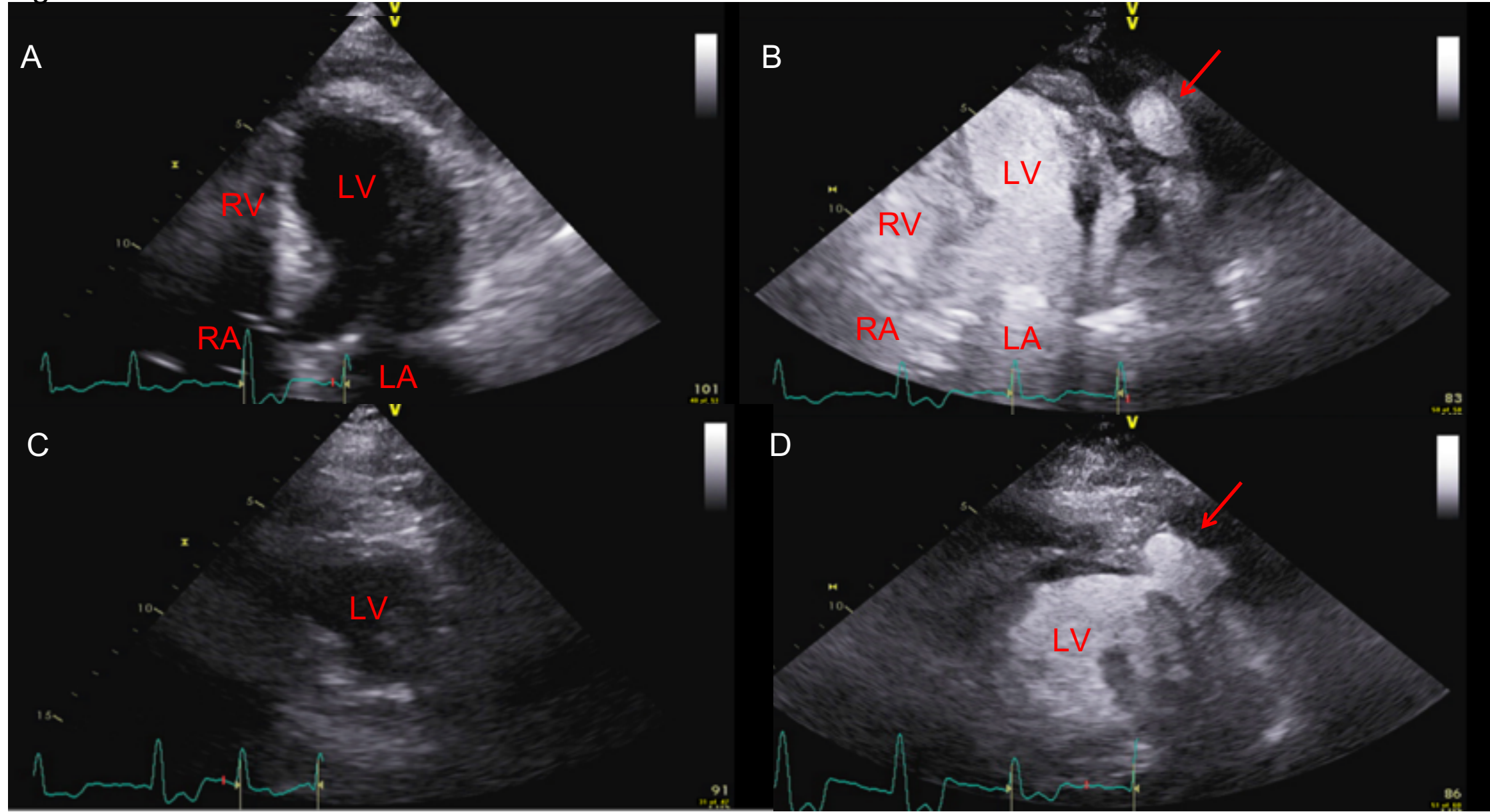


Figure 1



LV= Left Ventricle, RV= Right Ventricle, LA= Left Ventricle, RA= Right Ventricle,
Arrow=Pseudoaneurysm