

Esophageal lung complicated by recurrent pneumonia

Sushant Babbar¹ and Abhinandan Kumar¹

¹Post Graduate Institute of Medical Education and Research

May 3, 2023

Abstract

6 month old child presented with complaints of recurrent respiratory infection, tachypnea and decreased air entry on right side . Xray chest AP view (Fig[1](#fig-cap-0001)) showed opaque right hemithorax with ipsilateral mediastinal shift and compensatory hyperinflation of left lung. Further evaluation with CECT thorax (Fig [2](#fig-cap-0002)) showed hypoplastic right lung with collapse consolidation and right sided mediastinal shift. Bifurcation of trachea was not seen with trachea continuing as left main bronchus with normal segmental division. Right bronchus appears to be arising from lower part of esophagus, precise communication was not demonstrated (Fig [3](#fig-cap-0003)). Conventional contrast (non ionic) esophagogram was performed and free flow of contrast was seen from lower third of esophagus to the right main bronchus (Fig [4](#fig-cap-0004)) confirming the diagnosis of Congenital bronchopulmonary foregut malformation (CBPFM)

TITLE PAGE

TITLE: Esophageal lung complicated by recurrent pneumonia

First Author

Dr Abhinandan Kumar Senior Resident Department of Radiodiagnosis Post Graduate Institute of Medical Education and Research, Chandigarh Email : abhichandigarh16@gmail.com Phone : 9971626416

Conflict of Interest : None , Financial Disclosure : None

Corresponding Author

Dr Sushant Babbar Senior Resident Department of Radiodiagnosis Post Graduate Institute of Medical Education and Research, Chandigarh Email : sushant016@gmail.com Phone : 9805677533

Conflict of Interest : None , Financial Disclosure : None

Disclaimer : This material was not presented/published elsewhere. Informed consent was obtained for publishing images.

To the Editor

TITLE : Esophageal lung complicated by recurrent pneumonia

TEXT : 6 month old child presented with complaints of recurrent respiratory infection, tachypnea and decreased air entry on right side . Xray chest AP view (Fig1) showed opaque right hemithorax with ipsilateral mediastinal shift and compensatory hyperinflation of left lung. Further evaluation with CECT thorax (Fig 2) showed hypoplastic right lung with collapse consolidation and right sided mediastinal shift. Bifurcation of trachea was not seen with trachea continuing as left main bronchus with normal segmental division. Right bronchus appears to be arising from lower part of esophagus, precise communication was not demonstrated

(Fig 3). Conventional contrast (non ionic) esophagogram was performed and free flow of contrast was seen from lower third of esophagus to the right main bronchus (Fig 4) confirming the diagnosis of Congenital bronchopulmonary foregut malformation (CBPFM) 1. CBPFM consist of fistulous communication between respiratory and gastrointestinal tract and are more common in female child which usually present as recurrent episodes of choking while feeding, respiratory infection or failure depending upon type of malformation 2 with opacification and consolidation of involved lung is seen on imaging 3. It is classified by Srikanth et al¹ into 4 major types. Type 1A Total sequestered lung communicating with the foregut, associated with esophageal atresia and tracheoesophageal fistula to the distal pouch Type 1B: Sequestered anatomic lobe or segment communicating with the foregut, associated with esophageal atresia and tracheoesophageal fistula to the distal pouch, Type II: Total sequestered lung communicating with the lower esophagus; absent ipsilateral mainstem bronchus, Type III: Isolated anatomic lobe or segment communicating with the foregut and Type IV: Portion of the normal bronchial system communicating with the esophagus. Our case comes under category II in which right main bronchus is seen arising from distal esophagus. More commonly anomalous origin of right main bronchus is seen due to its proximity with esophagus⁴.

References

1. Srikanth MS, Ford EG, Stanley P, Mahour GH. Communicating bronchopulmonary foregut malformations: Classification and embryogenesis. *J Pediatr Surg.* 1992;27: 732-6.
2. Verma A, Mohan S, Kathuria M, Baijal SS. Esophageal bronchus: Case report and review of the literature. *Acta Radiol.* 2008;49:138–41.
3.) Bokka S, Jaiswal A, Behera B, Mohanty M, Khare M, Garg A. Esophageal lung: a rare type of communicating bronchopulmonary foregut malformation, case report with review of literature. *J Indian Assoc Pediatr Surg.* (2015) 20:92. doi: 10.4103/0971-9261.151558
4. Sur A, Sardar SK, Paria A. Left sided esophageal lung: A Diagnostic challenge. *Case Rep Pediatr* 2013. 2013:947401.

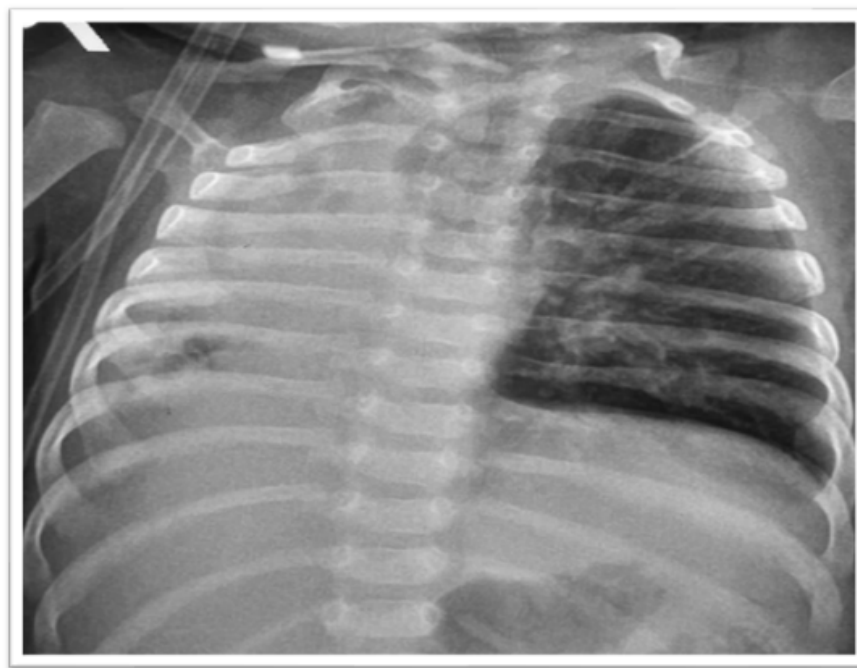


Figure 1: Chest xray AP view showing hazy right lung with ipsilateral mediastinal shift and hyperinflated left lung.

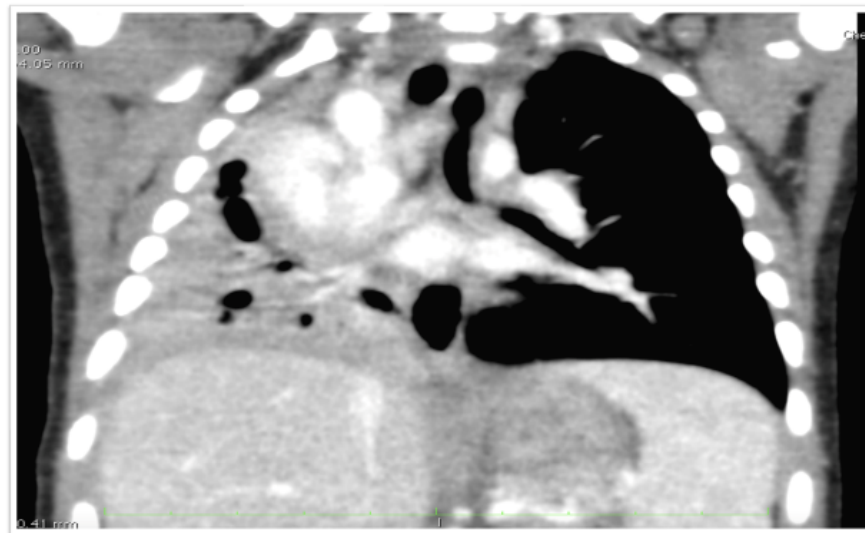


Figure 2: CECT show collapse consolidation of right lung with ipsilateral mediastinal shift.

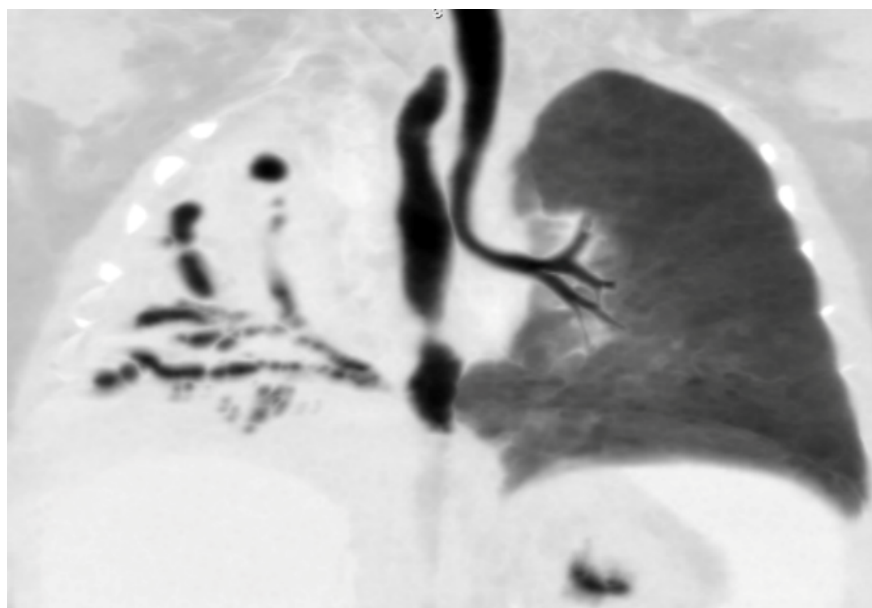


Figure 3: Minip images showing absent right main bronchus origin from trachea with normally arising left main bronchus. Right main bronchus appears to be arising from distal esophagus

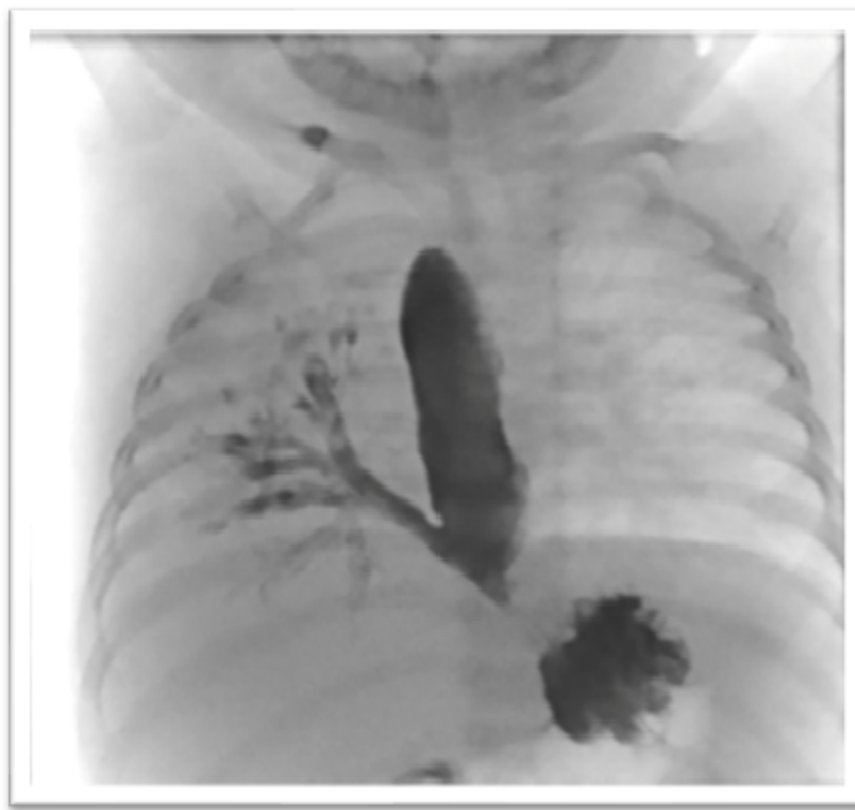

Figure 4: Conventional esophagogram demonstrating communication between right main bronchus and distal esophagus.

