

# Protracted Complete Response After Limited Checkpoint Inhibitor Dosing: A Case Report

Quinne Sember<sup>1</sup> and Darren Sigal<sup>1</sup>

<sup>1</sup>Scripps Health

April 28, 2023

## **Protracted Complete Response After Limited Checkpoint Inhibitor Dosing: A Case Report**

Authors:

Dr. Quinne Sember, MD Scripps Health

Dr. Darren Sigal, MD Scripps Health

Acknowledgements: None

Manuscript has not been presented

No disclaimers and no conflicts of interest.

Consent statement:

Written informed consent was obtained from the patient to publish this report in accordance with the journal's patient consent policy

Corresponding author:

Quinne Sember, MD

10710 North Torrey Pines Rd.

La Jolla, CA 92037

Phone: 716-574-6335

Email: [quinne@seember.net](mailto:quinne@seember.net)

Twitter: @SemberQuinne

## **Introduction**

Immunotherapy has emerged as an important treatment in many types of malignancy. In 2017, the FDA granted accelerated approval to pembrolizumab in the third line setting for patients with PD-L1 positive recurrent locally advanced or metastatic gastric or gastroesophageal junction adenocarcinoma based on the KEYNOTE-059 trial (1). In the KEYNOTE-062 trial, first line pembrolizumab for treatment of advanced gastric or EG junction adenocarcinoma was shown to be non-inferior to chemotherapy (2). Patients with a CPS score >10 in the trial had an improvement in overall survival compared to chemotherapy. Pembrolizumab now has approval for first-line treatment of these patients based on this trial. Many oncologists find immunotherapy to be particularly useful in patients who may not be ideal candidates to receive chemotherapy given its excellent side effect profile and ability to achieve a durable response. This has

made checkpoint inhibitor therapy standard of care in the first line setting in advanced or metastatic gastric adenocarcinoma with a CPS score  $>10$ .

There are many reports of patients who discontinue immunotherapy but continue to have a durable response, especially in those patients who experienced an immune-related adverse event (irAE). This has specifically been documented in melanoma, where the use of immunotherapy has become commonplace (3).

We present a case of a patient with metastatic gastric adenocarcinoma who received only three doses of pembrolizumab and sustained a prolonged response with near resolution of her disease nine months after the discontinuation of treatment.

## Case Report

The patient is an 89 year old female who presented for preoperative clearance for a knee replacement surgery in May 2020 and was found to have a pulmonary nodule on chest x-ray. She reported left sided abdominal pain after eating at that time. She underwent a CT scan of the chest which showed an irregularly shaped nonspecific density involving the left lower lobe of the lung measuring 11 mm as well as multiple bilateral pulmonary nodules measuring 2 to 4 mm. She then underwent a PET scan which showed a 6 cm hypermetabolic mass in the proximal stomach with associated hypermetabolic perigastric lymphadenopathy. The lung lesions were PET negative and thought to be non-malignant. She underwent an EGD in October 2020 which showed a fungating mass in the gastric cardiac. Pathology was consistent with a poorly differentiated invasive adenocarcinoma, intestinal type.

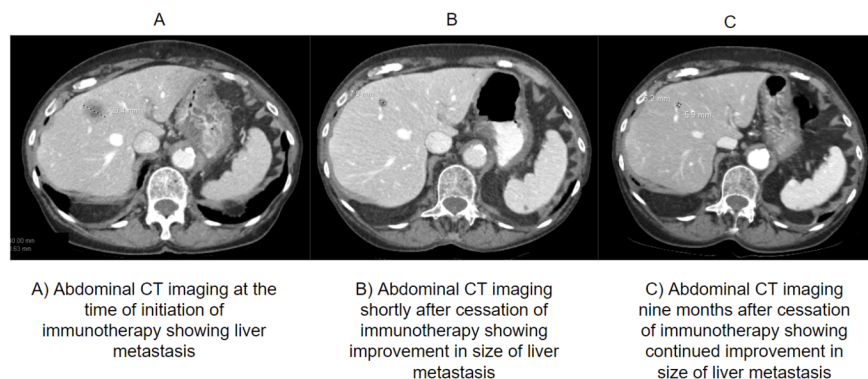
The patient was deemed not to be a surgical candidate due to advanced malignancy and age. She was started on chemoradiation with carboplatin and paclitaxel. She completed 45 Gray and 5 cycles of chemotherapy. A PET/CT following completion of these therapies showed multifocal PET avid metastatic disease in the liver as well as metastatic lymphadenopathy to the portacaval and left para-aortic lymph nodes. Next generation sequencing was obtained and showed a PD-L1 CPS score of 50.

In February 2021 the patient initiated pembrolizumab 200 mg IV every 3 weeks. After three cycles a surveillance CT in May 2021 showed resolution of the mass in the proximal stomach as well as resolution of the adjacent perigastric lymphadenopathy. Multiple subcentimeter low-density lesions were again visualized in the liver.

In June of 2021, after three cycles of immunotherapy, the patient developed a ruptured left knee popliteal cyst associated with significant pain. She became much more sedentary because of this and also began to experience lack of appetite and fatigue. Thyroid studies, ACTH, and morning cortisol were all within normal levels. There was therefore no evidence that this was related to treatment with immunotherapy at the time. Treatment was held to allow time for the patient to recover. She showed significant improvement and at follow-up in August 2021 was back to her baseline. CT imaging performed at that time showed a decrease in size in the hepatic lesions, with a decrease in the largest lesion from 2.6 cm to 0.8 cm. The portacaval and para-aortic lymph nodes were also noted to have decreased in size. The gastric mass was again not visualized. Given that the imaging showed continued improvement in the disease despite the patient not having received immunotherapy since May 2021, the decision was made to continue to monitor off of all therapy.

Imaging was again performed in February 2022 with only one of three liver metastases still visible (Figure 1). The previously identified portacaval lymph node had resolved. She was again continued off of therapy given the remarkable durable response she attained with only three doses of immunotherapy.

## Figure 1



## Discussion

Immunotherapy has become an important treatment in advanced and metastatic gastric adenocarcinoma. We present a case of an 89 year old woman who underwent treatment with pembrolizumab for metastatic gastric adenocarcinoma and discontinued the therapy after only three doses due to severe fatigue and poor appetite. While there was no laboratory evidence that the fatigue and appetite suppression she experienced were related to the immunotherapy, her fatigue and constitutional symptoms were profound, required hospitalization, and did likely represent an immune-related adverse event. Despite a short course of treatment, her disease continued to improve off of therapy and at the time of last follow-up, nine months after the last dose of immunotherapy, her only remaining disease was one metastasis in the liver.

Durable responses such as this have been documented in other forms of malignancy where immunotherapy is more commonly used, such as melanoma. However, melanoma is known to be a particularly immunogenic tumor, partially due to its high mutational burden (6). It is also understood that durable responses happen more frequently with treatment with immunotherapy than other cancer-directed therapies and that durable responses occur more frequently with PD-1 or PD-L1 inhibitors than with CTLA-4 inhibitors (10). As immunotherapy becomes more frequently used in other tumor types such as gastric adenocarcinoma, which are less immunogenic, it will be important to attempt to understand which patients may sustain these durable responses.

There is currently no standard definition of durable response and it is not understood why some patients develop a durable response while others do not. Check-point inhibitor therapy works by blocking either PD-1, PD-L1, or CTLA-4 which are proteins that when activated, prevent T-cells from killing tumor cells (4). When one or more of these proteins are blocked, a T-cell mediated immune response is stimulated to kill cancer cells. Once that response to tumor cells is stimulated, it probably does not require continued administration of the drug to maintain that response but not enough is understood about the immune response that develops.

One key to understanding this may be examination of tumor-infiltrating lymphocytes (TILs) (12). The presence of these cells in the tumor has been correlated with a positive response in a number of malignancies. TILs with a high PD-1 expression have been shown to be predictive of a response to checkpoint inhibitor therapy in patients with non-small cell lung cancer (13). Perhaps the presence and amount of TILs in the tumor could help predict which patients may have a durable response.

Patients who develop irAEs are known to be more likely to have durable responses to immunotherapy. In one study of melanoma patients, 81.2% of patients who discontinued immunotherapy due to an irAE had a durable response (3). This was true even in patients who did not have a complete response, which was previously thought to be uncommon based on KEYNOTE-001. These patients seem to develop an adaptive memory immune response that prolongs their response to therapy.

Radiologic response to treatment is another factor that is understood to be a predictor of durable response in melanoma patients. One study evaluated 104 patients with melanoma who received immunotherapy (14). 78 patients had a complete metabolic response (CMR) on PET scan at 1 year after the initiation of therapy. Of these patients, 78% then discontinued therapy. After a median follow-up time after discontinuation of therapy of 14.5 months, 96% of these patients remained progression free. Obtaining a CMR on PET therefore seems predictive that patients will have an ongoing response to treatment, regardless of whether they're continued on therapy or not.

The number of necessary doses of immunotherapy to continue after a radiologic response is identified is not well-defined. Most trials evaluating immunotherapy response, especially in patients with metastatic disease, have used 2 years of administration of the drug to mark a "completion" of therapy. This originated from the design of some of the first checkpoint inhibitor therapy trials in melanoma and has been utilized in most checkpoint inhibitor trials thereafter (8). This cut off for therapy completion was used in both the KEYNOTE-059 and KEYNOTE-062 trials in gastric adenocarcinoma (1, 2). The KEYNOTE-001 trial in melanoma had a protocol amendment that allowed patients who had a complete response and who had received immunotherapy for 6 months to discontinue treatment after they had received additional 2 doses of immunotherapy following the imaging on which they were assessed to have had a complete response (15). Otherwise, there has been a somewhat pervasive use of the seemingly arbitrary cut off of 2 years of treatment in trials. This has influenced the way most oncologists practice, especially as there is limited data to suggest a different approach.

Trials examining the appropriate duration of immunotherapy are slowly becoming more common. An exploratory analysis of the Checkmate 153 trial, which evaluated the use of nivolumab in patients with advanced or metastatic non-small cell lung cancer, was performed to examine whether using a fixed duration of 1 year of therapy or continuing nivolumab after 1 year impacted outcomes. The patients were randomly assigned to the two groups. Both progression free survival and overall survival were improved with continued therapy (11). This may have been due to the fact that patient response assessment or any other patient factors were not used to decide whether or not to continue therapy after 1 year.

The HIMALAYA trial in hepatocellular carcinoma showed that a single priming dose of tremelimumab (a CTLA-4 inhibitor), given with durvalumab (a PD-L1 inhibitor), was sufficient to confer ongoing benefit when only durvalumab was continued (7). There was a 30.7% three year overall survival with the single dose of tremelimumab plus ongoing durvalumab versus a 24.7% three year overall survival with durvalumab given alone. This trial demonstrates that immune surveillance likely persists once it is triggered, even with a single dose of combination immunotherapy.

There are some trials under way in melanoma to help better determine the appropriate duration of immunotherapy. These trials are using various measures of patient response assessments to determine which patients stop therapy and which patients continue. For example, the Safe Stop Trial is currently evaluating whether it is safe to discontinue immunotherapy at the time of complete or even partial response in patients with melanoma (9).

While trials are ongoing in melanoma, very little research is being conducted to understand the appropriate duration of therapy in other malignancies, such as in gastrointestinal malignancies. Cases such as ours, in which patients discontinue immunotherapy and have durable responses, need to be continually reported and evaluated. Some patients, including those with GI malignancies, may only require a short duration of immunotherapy to derive long-term benefit. This case report indicates that some patients who experience immune related adverse events requiring discontinuation of therapy may experience a period of protracted remission and need not immediately plan for alternative systemic therapy options.

Identifying the appropriate length of treatment in these patients will be an important aspect in ongoing efforts to improve value-based care for patients in oncology. Immunotherapy is often much more expensive than chemotherapy. Pembrolizumab is about \$10,000 per dose and nivolumab is about \$7,000 per dose (16,17). Patients often receive months or years of these therapies after they've had a documented remission.

If patients who may have a protracted complete response to immunotherapy are identified early, hundreds of thousands of dollars per patient could likely be saved. It would also reduce the burden on the healthcare system as these patients would not need appointments for infusions or frequent labs and follow-up visits. It is imperative that research be pursued to better understand the appropriate length of immunotherapy treatment for individualized patients.

## References

1. Fuchs CS, et al. Safety and Efficacy of Pembrolizumab Monotherapy in Patients With Previously Treated Advanced Gastric and Gastroesophageal Junction Cancer: Phase 2 Clinical KEYNOTE-059 Trial. *JAMA Oncol.* 2018 May 10;4(5):e180013. doi: 10.1001/jamaoncol.2018.0013. Epub 2018 May 10. Erratum in: *JAMA Oncol.* 2019 Apr 1;5(4):579. PMID: 29543932; PMCID: PMC5885175.
2. Shitara K, et al. Efficacy and Safety of Pembrolizumab or Pembrolizumab Plus Chemotherapy vs Chemotherapy Alone for Patients With First-line, Advanced Gastric Cancer: The KEYNOTE-062 Phase 3 Randomized Clinical Trial. *JAMA Oncol.* 2020 Oct 1;6(10):1571-1580. doi: 10.1001/jamaoncol.2020.3370. PMID: 32880601; PMCID: PMC7489405.
3. Swami U, Monga V, Bossler AD, Zakharia Y, Milhem M. Durable Clinical Benefit in Patients with Advanced Cutaneous Melanoma after Discontinuation of Anti-PD-1 Therapies Due to Immune-Related Adverse Events. *J Oncol.* 2019;2019:1856594. Published 2019 Jul 25. doi:10.1155/2019/1856594
4. Borcoman, E., et al. "Novel Patterns of Response under Immunotherapy." *Annals of Oncology*, vol. 30, no. 3, 2019, pp. 385–396., <https://doi.org/10.1093/annonc/mdz003>.
5. Mulder EEAP, de Joode K, Litière S, Ten Tije AJ, Suijkerbuijk KPM, Boers-Sonderen MJ, Hospers GAP, de Groot JWB, van den Eertwegh AJM, Aarts MJB, Piersma D, van Rijn RS, Kapiteijn E, Vreugdenhil G, van den Bergmortel FWPJ, Hoop EO, Franken MG, Ryll B, Rutkowski P, Sleijfer S, Haanen JBag, van der Veldt AAM. Early discontinuation of PD-1 blockade upon achieving a complete or partial response in patients with advanced melanoma: the multicentre prospective Safe Stop trial. *BMC Cancer.* 2021 Mar 25;21(1):323. doi: 10.1186/s12885-021-08018-w. PMID: 33765967; PMCID: PMC7993897.
6. Passarelli, Anna et. al. "Immune system and melanoma biology: a balance between immunosurveillance and immune escape." *Oncotarget* vol. 8,62 106132-106142. 31 Oct. 2017, doi:10.18632/oncotarget.22190
7. Abou-Alfa, G. K., et. al. (2022). Phase 3 randomized, open-label, Multicenter Study of Tremelimumab (T) and durvalumab (D) as first-line therapy in patients (PTS) with unresectable hepatocellular carcinoma (uHCC): Himalaya. *Journal of Clinical Oncology*,40(4-suppl), 379–379. <https://doi.org/10.1200/jco.2022.40.4-suppl.379>
8. Robert, C., Schachter, J., Long, G. V., Arance, A., Grob, J. J., Mortier, L., Daud, A., Carlino, M. S., McNeil, C., Lotem, M., Larkin, J., Lorigan, P., Neyns, B., Blank, C. U., Hamid, O., Mateus, C., Shapira-Frommer, R., Kosh, M., Zhou, H., ... Ribas, A. (2015). Pembrolizumab versus Ipilimumab in advanced melanoma. *New England Journal of Medicine*, 372(26), 2521–2532. <https://doi.org/10.1056/nejmoa1503093>
9. Mulder, E.E.A.P., de Joode, K., Litiere, S. *et al.* Early discontinuation of PD-1 blockade upon achieving a complete or partial response in patients with advanced melanoma: the multicentre prospective Safe Stop trial. *BMC Cancer* 21, 323 (2021).<https://doi.org/10.1186/s12885-021-08018-w>
10. Pons-Tostivint, E., Latouche, A., Vaffard, P., Ricci, F., Loirat, D., Hescot, S., Sablin, M.-P., Rouzier, R., Kamal, M., Morel, C., Lecerf, C., Servois, V., Paoletti, X., & Le Tourneau, C. (2019). Comparative analysis of durable responses on immune checkpoint inhibitors versus other systemic therapies: A pooled analysis of phase III trials.*JCO Precision Oncology*, (3), 1–10. <https://doi.org/10.1200/po.18.00114>
11. Waterhouse, D. M., Garon, E. B., Chandler, J., McCleod, M., Hussein, M., Jotte, R., Horn, L., Daniel, D. B., Keogh, G., Creelan, B., Einhorn, L. H., Baker, J., Kasbari, S., Nikolinakos, P., Babu, S., Couture, F., Leighl, N. B., Reynolds, C., Blumenschein, G., ... Spigel, D. R. (2020). Continuous versus 1-year fixed-duration nivolumab in previously treated advanced non-small-cell lung cancer: Checkmate 153.

- Journal of Clinical Oncology*, 38(33), 3863–3873. <https://doi.org/10.1200/jco.20.00131>
12. Zhang, Yuanyuan, and Zemin Zhang. “The history and advances in cancer immunotherapy: understanding the characteristics of tumor-infiltrating immune cells and their therapeutic implications.” *Cellular & molecular immunology* vol. 17,8 (2020): 807-821. doi:10.1038/s41423-020-0488-6
  13. Thommen DS, Koelzer VH, Herzig P, Roller A, Trefny M, Dimeloe S, Kiialainen A, Hanhart J, Schill C, Hess C, Savic Prince S, Wiese M, Lardinois D, Ho PC, Klein C, Karanikas V, Mertz KD, Schumacher TN, Zippelius A. A transcriptionally and functionally distinct PD-1+ CD8+ T cell pool with predictive potential in non-small-cell lung cancer treated with PD-1 blockade. *Nat Med*. 2018 Jul;24(7):994-1004. doi: 10.1038/s41591-018-0057-z. Epub 2018 Jun 11. PMID: 29892065; PMCID: PMC6110381.
  14. A.C. Tan, L. Emmett, S. Lo, V. Liu, R. Kapoor, M.S. Carlino, A.D. Guminski, G.V. Long, A.M. Menzies. FDG-PET response and outcome from anti-PD-1 therapy in metastatic melanoma. *Annals of Oncology*, Volume 29, Issue 10, 2018. Pages 2115-2120. <https://doi.org/10.1093/annonc/mdy330>.
  15. O. Hamid, C. Robert, A. Daud, F.S. Hodi, W.J. Hwu, R. Kefford, J.D. Wolchok, P. Hersey, R. Joseph, J.S. Weber, R. Dronca, T.C. Mitchell, A. Patnaik, H.M. Zarour, A.M. Joshua, Q. Zhao, E. Jensen, S. Ahsan, N. Ibrahim, A. Ribas. Five-year survival outcomes for patients with advanced melanoma treated with pembrolizumab in KEYNOTE-001. *Annals of Oncology*, Volume 30, Issue 4, 2019.<https://doi.org/10.1093/annonc/mdz011>.
  16. *Cost info & financial help*. Cost Information and Financial Help With KEYTRUDA(r) (pembrolizumab) | Patients. (n.d.). Retrieved November 18, 2022, from <https://www.keytruda.com/financial-support/>
  17. *Pricing information*. Cost & Pricing Information | OPDIVO(r) (nivolumab) and OPDIVO-based Combinations. (n.d.). Retrieved November 18, 2022, from <https://www.bmspricinginformation.com/opdivo>