

primary mediastinal yolk sac tumor: a case report and literature review

Diqing Wu¹, Kun Zhang², and Xueqin Zhang²

¹Suzhou Hospital of Anhui Medical University,

²Suzhou Hospital of Anhui Medical University

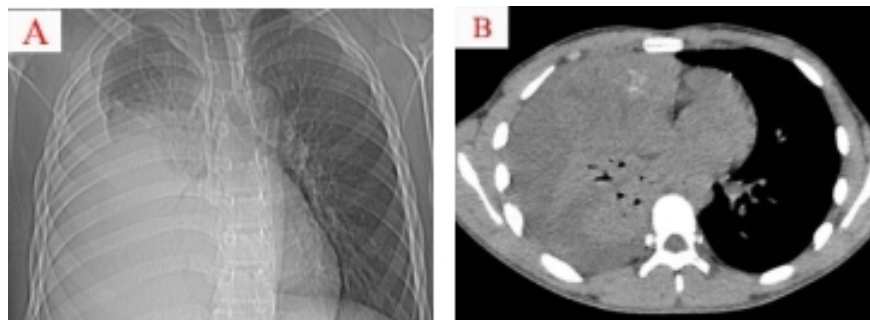
March 27, 2023

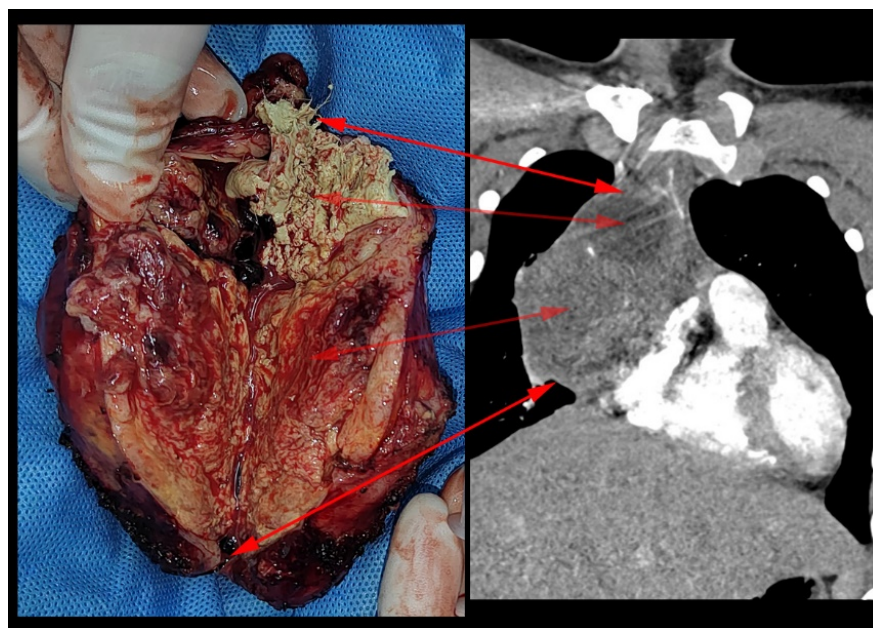
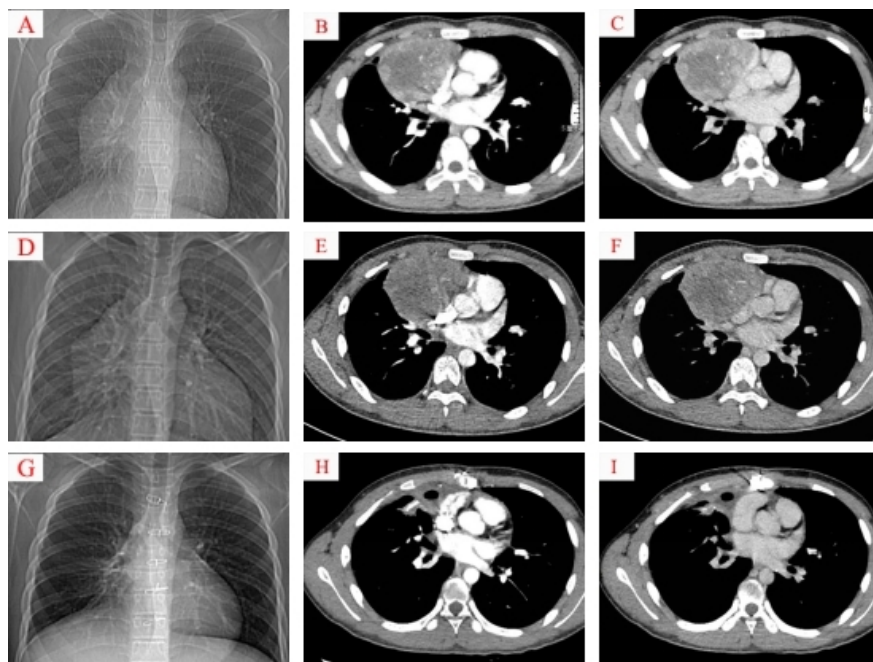
Abstract

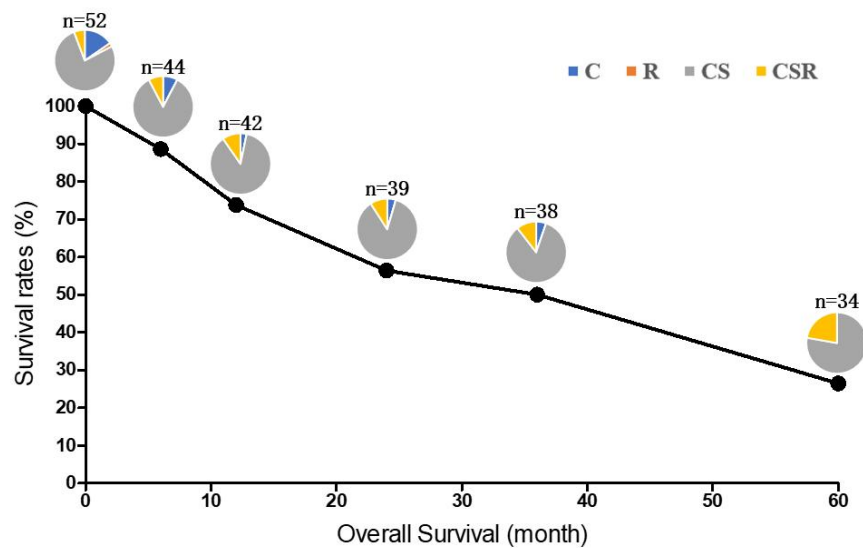
Background: The purpose of this article is armed to provide some experience and insight for the clinical treatment of primary mediastinal yolk sac tumor (PMYST) basing on our case report and relevant literature review. Case report and literature review: A 15-year-old boy was diagnosed as PMYST with the volume about 13*12*8cm. The

Hosted file

1.manuscript(2).docx available at <https://authorea.com/users/600310/articles/631956-primary-mediastinal-yolk-sac-tumor-a-case-report-and-literature-review>







Hosted file

Table 1.docx available at <https://authorea.com/users/600310/articles/631956-primary-mediastinal-yolk-sac-tumor-a-case-report-and-literature-review>