

# Shape-Sensing Robotic Bronchoscopy in the Diagnosis of Pulmonary Lesions in Children.

Guillermo Beltran Ale<sup>1</sup>, Ryne Simpson<sup>1</sup>, Christopher Mertens<sup>1</sup>, Elsa Santillana<sup>1</sup>, Benjamin Hill<sup>2</sup>, Waldermar Carlo<sup>3</sup>, and Hitesh Batra<sup>1</sup>

<sup>1</sup>University of Alabama at Birmingham

<sup>2</sup>Children's of Alabama

<sup>3</sup>The University of Alabama at Birmingham Department of Pediatrics

November 12, 2022

## Abstract

To our knowledge, this is the first reported case of successful transbronchial biopsy via RB in a 5-year-old patient. The sample revealed a potential diagnosis, but more importantly, helped rule out an active infectious process and avoided an open lung biopsy which was being planned and would have otherwise been necessary to establish a diagnosis. We believe this technology can be used to increase the diagnostic yield of flexible bronchoscopy, particularly in the immunocompromised population as there is already evidence supporting image-guided bronchoscopy over conventional bronchoscopy in this population [(4)](#ref-0004). A notable limitation to RB is the size of the available bronchoscopes for robotic platforms (4.5 and 3.5 mm OD). In children, this may limit the capacity to sample more peripheral lesions via fine needle aspiration, as more lung tissue (relative to chest size) may be injured. In our case, the catheter tip was never as close to the lesion as it has been described in adults [(2)](#ref-0002). As the field of pediatric interventional pulmonology continues to develop, RB will likely be one of several options available for safe and high-yield diagnostic procedures.

## Clinical Correspondance

### Title:

Shape-Sensing Robotic Bronchoscopy in the Diagnosis of Pulmonary Lesions in Children.

### Authors:

Guillermo Beltran-Ale<sup>1,2</sup>, Ryne Simpson<sup>1,2</sup>, Christopher Mertens<sup>1,2</sup>, Elsa Santillana<sup>3,4</sup>, Benjamin Hill<sup>5</sup>, Waldermar Carlo<sup>2,6</sup>, Hitesh Batra<sup>3,4</sup>

<sup>1</sup>Division of Pediatric Pulmonary and Sleep Medicine, University of Alabama at Birmingham, Birmingham, Alabama

<sup>2</sup>Department of Pediatrics, University of Alabama at Birmingham, Birmingham, Alabama

<sup>3</sup>Division of Pulmonary, Allergy, and Critical Care Medicine, University of Alabama at Birmingham, Birmingham, Alabama

<sup>4</sup>Department of Medicine, University of Alabama at Birmingham, Birmingham, Alabama

<sup>5</sup>Department of Pathology, Children's of Alabama, Birmingham, Alabama

<sup>6</sup>Division of Pediatric Cardiology, University of Alabama at Birmingham, Birmingham, Alabama

### Financial Disclosure:

The authors declare they have no relevant financial interests.

## Conflicts of Interest:

Dr. Hitesh Batra serves as a consultant and proctor for Intuitive.

## Key Words:

Robotic Bronchoscopy, Interventional Pulmonology, Children, Navigational Bronchoscopy

## Correspondence to:

Guillermo Beltran Ale, MD

University of Alabama – Birmingham

Department of Pediatrics, Division of Pulmonary and Sleep Medicine

620 Jarman F. Lowder Building

1600 7<sup>th</sup> Avenue South

Birmingham, AL 35233

Email: [gjbeltranale@uabmc.edu](mailto:gjbeltranale@uabmc.edu)

## To the Editor,

Robotic bronchoscopy (RB) is becoming a preferred method for sampling peripheral pulmonary lesions in adults. RB allows preparation for the procedure using a planning software and provides direct visualization of the airways while simultaneously controlling the location of the scope assisted by a virtual 3-D reconstruction. Accuracy of navigation is verified with fluoroscopy and/or radial probe ultrasound (rEBUS) during the procedure (1). In adults, there is growing evidence that RB can increase diagnostic yield while minimizing complications (2). Alternative methods include percutaneous CT guided biopsy which lacks the ability to biopsy multiple lesions and carries a higher risk of complications, as well as conventional bronchoscopy which is often unable to maneuver into more peripheral lesions. Published data for RB report a diagnostic yield of 69 – 88% and a 0 - 3.8% rate of pneumothorax (3).

We are aware of unpublished experiences using RB in teenagers and cone-beam CT guided bronchoscopy in younger children. There is minimal-to-no published data of the use of RB in the latter group. As one of the available platforms utilizes a scope with a 3.5 mm outer diameter (OD) it could be used in small children. Here, we present a case demonstrating the utility of RB in a 5-year-old with peripheral pulmonary lesions.

## Case

A 116 cm, 20.9 kg 5-year-old post orthotopic heart transplant for dilated cardiomyopathy presented with right-sided peripheral pulmonary opacities on chest CT. She had previously completed intravenous antifungal therapy for *Rhinochlamydia similis* fungemia acquired while on left ventricular assist device support. CT revealed the development of numerous ill-defined, nodular opacities within all lobes of the right lung and several small areas of calcification in the right middle and lower lobes (Figure 1). Flexible bronchoscopy with bronchoalveolar lavage (BAL) was performed, however, broad testing failed to yield a diagnosis. Oral antifungal therapy was continued with plans for repeat imaging in 1 month. CT again revealed right-sided nodules in a similar distribution, but with increased density (-200 versus -450 Hounsfield units). In addition, several left-sided nodules had developed in the lingula and left upper lobe. Due to the clinical history and radiographic evolution, tissue biopsy was requested. Because of the patient's size and peripheral location of the nodules, biopsy using the Intuitive Ion<sup>TM</sup> Robotic Bronchoscopy system was attempted to avoid percutaneous biopsy or video assisted thoracoscopy.

## Procedure

The Ion™ Endoluminal System by Intuitive was used. A CT with 1.5 mm thick slices was uploaded into the PlanPoint™ software. After airway segmentation by the software, target lesions were identified in both the right upper and lower lobes, pathways were planned and reviewed through a virtual simulation. The patient was intubated with a 6.0 endotracheal tube (ETT). A 4.2 mm bronchoscope (Olympus BF-P190™) was first used to complete a standard airway examination and aspirate secretions. The Ion system was then docked to the ETT via a magnetic adapter and the 3.5mm catheter with the vision probe inside it was inserted into the ETT. A standard registration including verification of the main carina and airways in each of the four quadrants was performed. The catheter was then navigated close to the right lower lobe target lesion under direct visualization and in accordance with the virtual navigation path created using the pre-procedure CT scan. Due to the small size of sub-segmental airways, we could not get closer than 22 mm from the RUL target nodule, and 32 mm from the RLL target nodule. However, we chose the RLL target for biopsy as we were able to introduce the catheter into an airway leading directly to the nodule (Figure 2). There was no appreciable CT-to-body divergence. The vision probe was then removed, and a rEBUS probe was inserted, which revealed a concentric signal. The rEBUS probe was then removed and multiple forceps biopsies were performed using the Olympus EndoJaw Disposable Biopsy Forceps with fluoroscopic guidance using an overlay of an image of the rEBUS probe extended to the distal end of the nodule. After several pieces of tissue were obtained, a BAL was performed. There were no immediate complications and a post-operative chest X-ray was unremarkable without evidence of pneumothorax.

The infectious work up was again negative. The pathology slides showed benign, distorted/hemorrhagic lung parenchyma with minimal inflammatory infiltrate, occasional hemosiderin-laden macrophages and several foci of dystrophic calcification (Figure 1). Due to right-sided unilaterality, vascular dysfunction was considered but CT angiography, trans-esophageal echocardiogram, and cardiac catheterization showed normal flow within the right-sided vessels and anastomosis.

## Discussion

To our knowledge, this is the first reported case of successful transbronchial biopsy via RB in a 5-year-old patient. The sample revealed a potential diagnosis, but more importantly, helped rule out an active infectious process and avoided an open lung biopsy which was being planned and would have otherwise been necessary to establish a diagnosis. We believe this technology can be used to increase the diagnostic yield of flexible bronchoscopy, particularly in the immunocompromised population as there is already evidence supporting image-guided bronchoscopy over conventional bronchoscopy in this population (4). A notable limitation to RB is the size of the available bronchoscopes for robotic platforms (4.5 and 3.5 mm OD). In children, this may limit the capacity to sample more peripheral lesions via fine needle aspiration, as more lung tissue (relative to chest size) may be injured. In our case, the catheter tip was never as close to the lesion as it has been described in adults (2). As the field of pediatric interventional pulmonology continues to develop, RB will likely be one of several options available for safe and high-yield diagnostic procedures.

The patient was considered to have metastatic pulmonary calcifications. These lesions are benign, and have been reported to self-resolve as there are no available treatment options (5). This entity has been described after infectious process, associated with renal failure and severe calcium or phosphorus abnormalities (5) and as isolated findings after liver or heart transplants (5). Follow-up imaging continues to demonstrate the same lesions without evidence of progression, and the patient remained asymptomatic.

## References

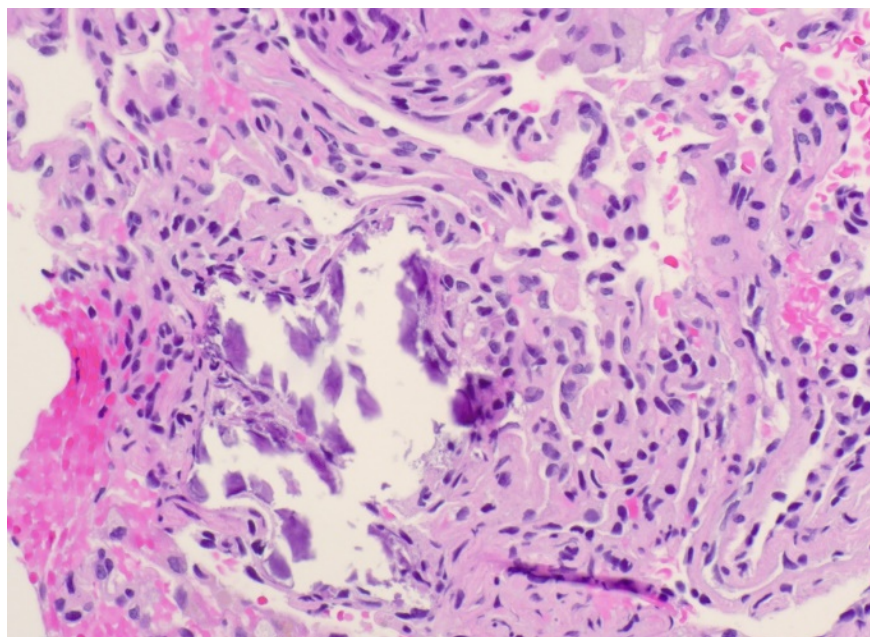
1. Lin J, Ost DE. Robotic bronchoscopy for peripheral pulmonary lesions: a convergence of technologies. *Curr Opin Pulm Med*. 2021;27(4):229-39.
2. Chen AC, Pastis NJ, Jr., Mahajan AK, Khandhar SJ, Simoff MJ, Machuzak MS, et al. Robotic Bronchoscopy for Peripheral Pulmonary Lesions: A Multicenter Pilot and Feasibility Study (BENEFIT). *Chest*. 2021;159(2):845-52.
3. Folch E, Mittal A, Oberg C. Robotic bronchoscopy and future directions of interventional pulmonology.

Curr Opin Pulm Med. 2022;28(1):37-44.

4. Bouso JM, Yendur O, Hysinger E, Planet PJ, Haas A, Goldfarb S, et al. Endobronchial Ultrasound-guided Biopsy Is Feasible, Safe, and Improves Diagnostic Yields in Immunocompromised Children. *Am J Respir Crit Care Med*. 2020;201(3):384-6.

5. AlNuaimi D, ElKaissi M, Wahla A, Shafiq I, Abdulghaffar S. Metastatic pulmonary calcifications post-cardiac transplant in a 15-year-old patient: A case report and review of literature. *Radiol Case Rep*. 2020;15(10):1978-82.

**Figure 1: Chest CT showing parenchymal opacities in the right middle lobe and right lower lobe. Lesions in the right lower lobe were peripheral and had not increased in volume but changed density within 4 weeks. Trans-bronchial lung biopsy slide showing alveolar cells and 1 center of dystrophic calcification.**



**Figure 2: RB platform screen. In the upper portion the virtual navigation path with lesions colored dark green and pleural space colored purple. Below this, an image indicating the distance from the tip of the scope (bright green) to the identified lesions (light blue oval). In the lower portion a fluoroscopic image showing both the forceps and the rEBUS probe overlay image and on the left side the virtual bronchoscopy view and rEBUS signal.**

