

Gastric ischemia and pulmonary embolism in a patient with acute leukemia

Sondes Bizid¹, Fatma Ben Farhat¹, Younes Arous¹, and Sonia Bennaser¹

¹Military Hospital of Instruction of Tunis

October 18, 2022

Abstract

A Tunisian male diagnosed with an acute lymphoblastic leukemia was admitted to our hospital for a chemotherapy cure . During the hospitalization, he presented an acute epigastric pain with fever. Abdominal CT scan showed circumferential gastric thickening with an enhancement defect suggestive of gastric ischemia associated with segmental pulmonary embolism.

Gastric ischemia and pulmonary embolism in a patient with acute leukemia

Author list:

Sondes BIZID ^{1,4}, Fatma BEN FARHAT^{1,4}, Younes AROUS^{2,4}, Sonia BENNASER^{3,4}

1.Gastro-enterology Department , Military hospital of Tunis, Tunis, Tunisia

2.Radiology Department, Military hospital of Tunis, Tunis, Tunisia

3.Oncology Department, Military hospital of Tunis, Tunis, Tunisia

4.University of Tunis El Manar, Faculty of Medicine, 1007, Tunis, Tunisia

[✉]Corresponding author:

Fatma Ben Farhat,

University of Tunis El Manar, Faculty of Medicine of Tunis, 1007, Tunis, Tunisia

The military hospital of Tunis, Department of Gastroenterology, Montfleury 1008, Tunisia

Email: *Fatmabf8@gmail.com*

Consent:

Written informed consent was obtained from the patient to publish this report in accordance with the journal's patient consent policy.

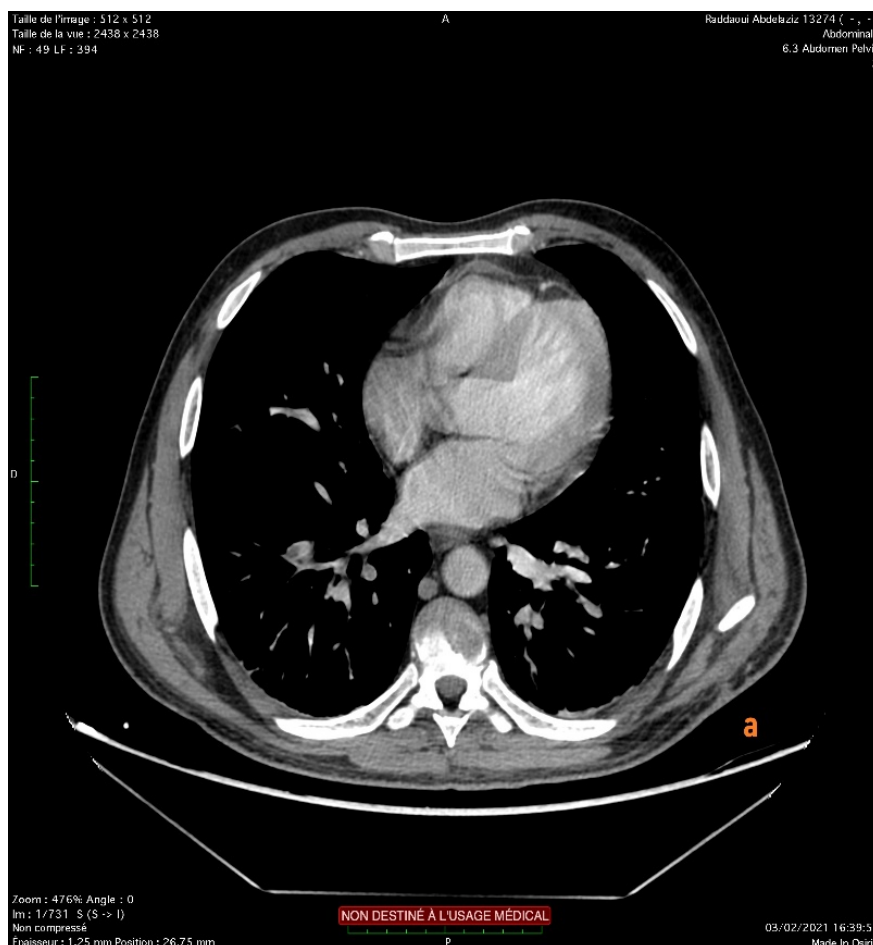
Competing interests

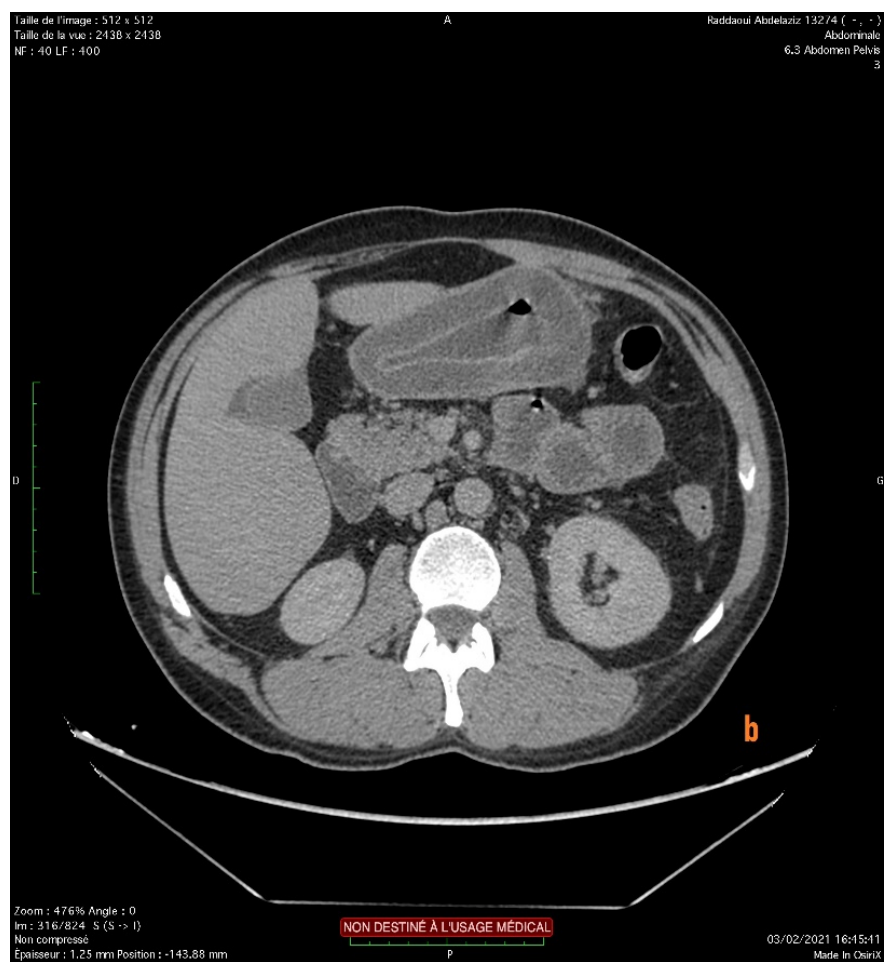
The authors declare no competing interest.

Case

A 41-year-old Tunisian male diagnosed with an acute lymphoblastic leukemia was admitted to our hospital for a chemotherapy cure (Hyper-CVAD: Cyclophosphamide, Vincristine Sulfate, Doxorubicin Hydrochloride and Dexamethasone). During the hospitalization, he presented an acute epigastric pain with hemodynamic instability and fever. Physical examination revealed abdominal tenderness. The thoraco-abdominal CT

scan showed circumferential gastric thickening with an enhancement defect suggestive of gastric ischemia associated with segmental pulmonary embolism (Figure 1). He was treated with noradrenaline, intravenous fluids, intravenous proton pump inhibitors, broad-spectrum antibiotics and anticoagulants with favorable clinical outcome. At day 7, he underwent an upper endoscopy. It revealed hypertrophic, ulcerated fundic folds covered with false membranes with necrotic foci, extending from the proximal body to the proximal antrum (Figure 2). Histology was compatible to the endoscopic suspicion of gastric ischemia. The patient was discharged after 2 weeks of medical treatment and was reevaluated at 1 month, remaining asymptomatic.





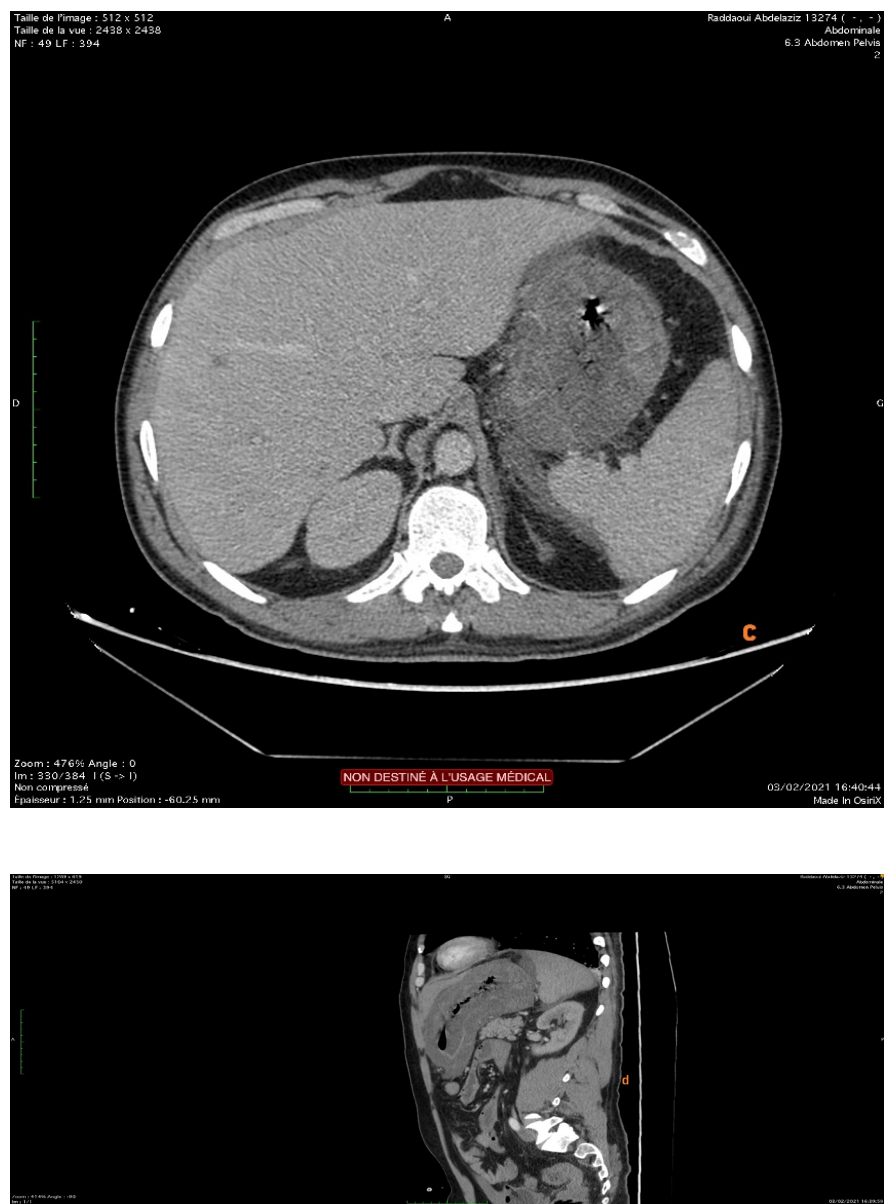
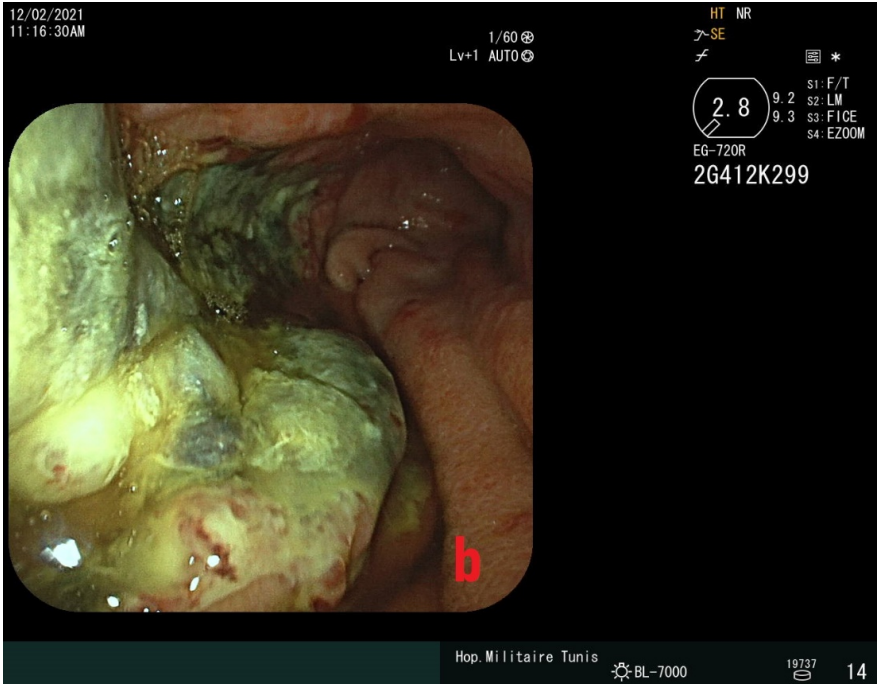
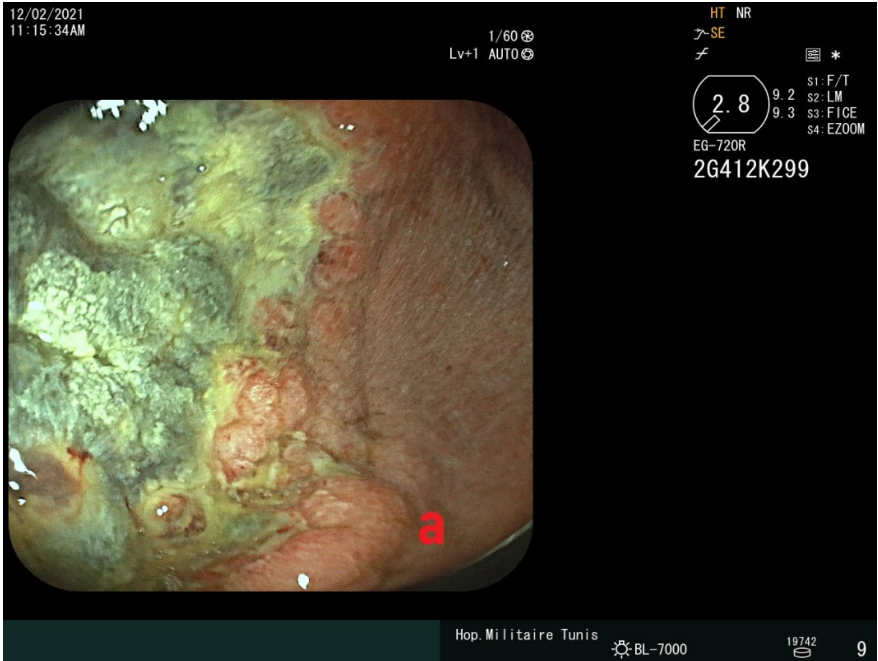

Figure 1: CT scan findings: a- segmental pulmonary embolism
 b,c,d- circumferential gastric thickening with an enhancement defect



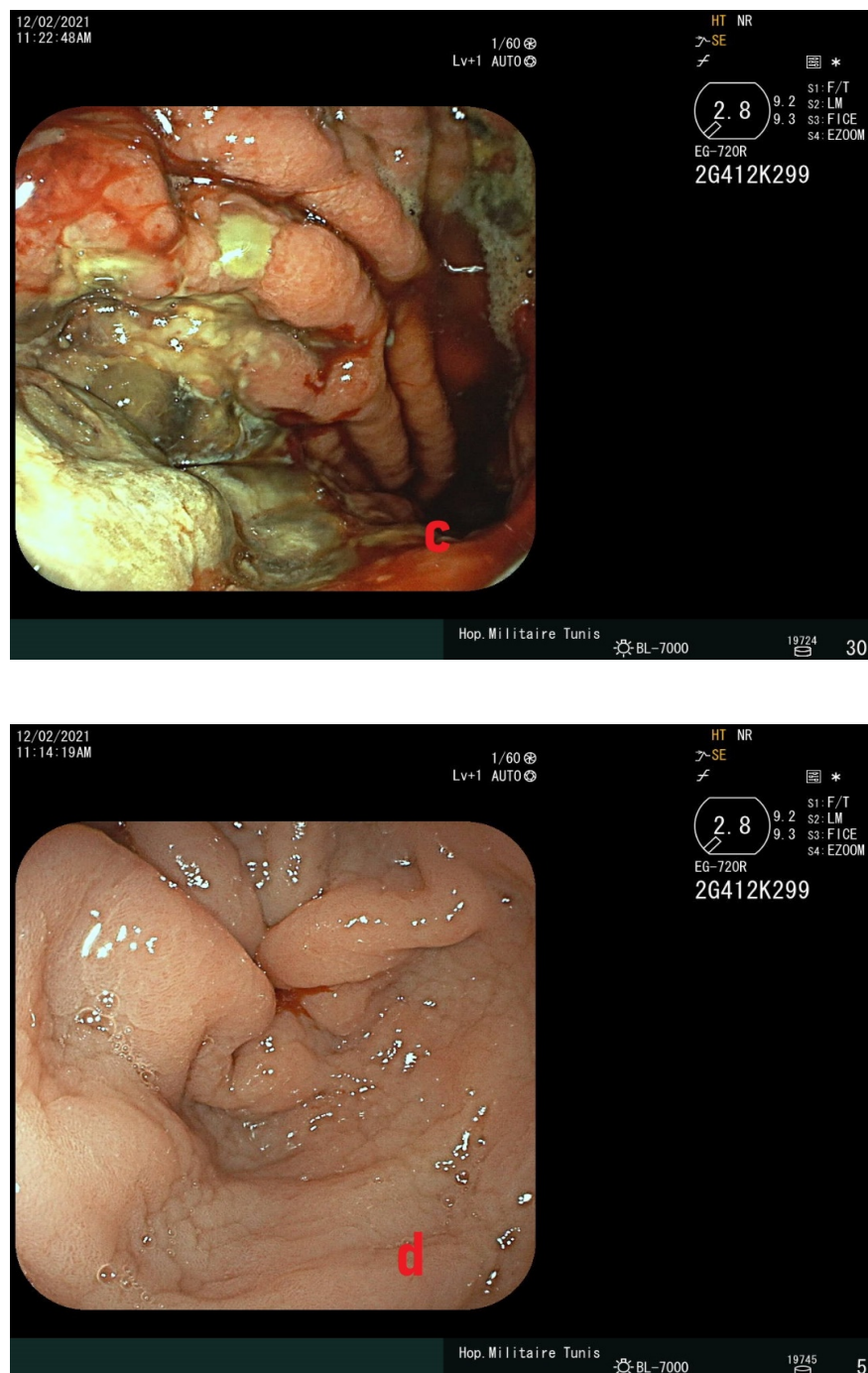


Figure 2 : endoscopy findings a and b-necrosis foci
c- ulcerated fundic folds
d- antral mucosa